

Vascular lab report

Assessed by: Suleman Choudhury

Anterior view

Posterior view

Right GSV:

Proximal thigh- 12mm
]Mid-thigh- 11mm
Distal thigh- 11mm

Proximal calf – 11mm
Mid-calf – 7mm
Distal calf – 3mm

The GSV lies straight throughout, although leaves the fascia at knee level.



red colour denotes reflux



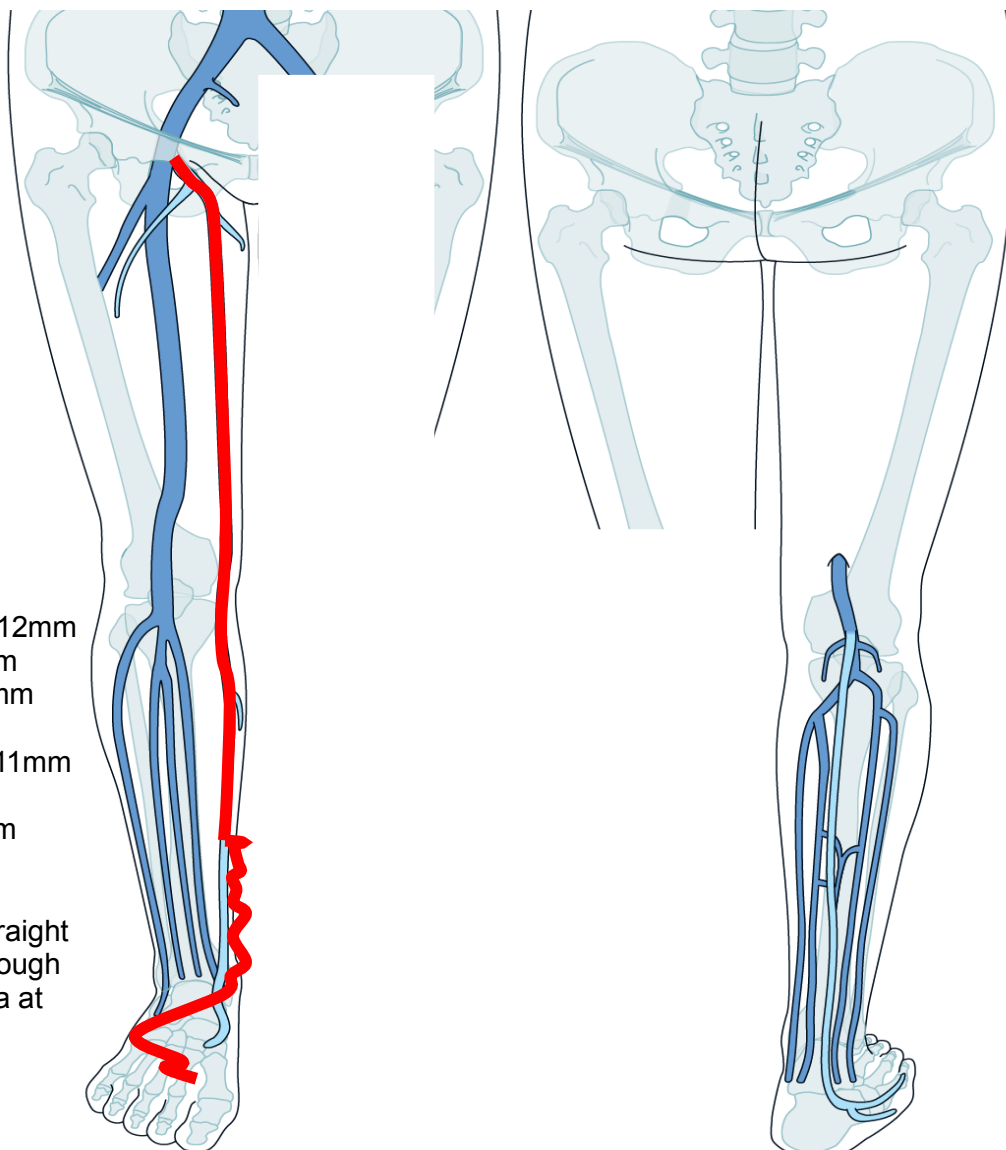
Competent superficial vein



Competent deep vein



Deep vein scarring



US Doppler lower limb veins Rt:

The Sapheno-Femoral Junction (SFJ) and Greater Saphenous vein (GSV) are patent and incompetent. The GSV fills a varicose vein (9mm) in the mid-calf which courses medially to the foot.

The Sapheno-Popliteal Junction (SPJ) and Short Saphenous vein (SSV) are patent and competent.

All deep veins are all patent and competent.

No incompetent perforators detected.
